

Supplement to

October 2022

Sponsored by

CRST

EUROPE

Cataract & Refractive Surgery Today



Celebrating the Magic of Vision

30 years of SCHWIND laser systems.



SCHWIND eye-tech-solutions: Celebrating 30 Years of Excellence

A family business focused on customer relations.

BY ROLF SCHWIND AND DOMENIC VON PLANTA

This year marks the 30th anniversary of SCHWIND. Today, we stand as a pioneer in refractive corneal surgery, driving solutions for vision correction procedures and building strong relationships with our customers with one common goal in mind: to improve the lives of those with refractive errors.

THE SCHWIND FAMILY PHILOSOPHY

SCHWIND is a medium-sized company that is deeply rooted in the personal connections we have with our customers. In this sense, our customers see us as more than a manufacturer—they see us as a partner. We have worked together over the years to continually develop and improve our excimer (SCHWIND AMARIS) and femtosecond (SCHWIND ATOS) laser platforms as well as our procedure offerings. These include, among others, touch-free SmartSurf^{FACE} (TransPRK) surface ablation treatments, SmartLASIK (intraström femtosecond LASIK), PresbyMax for presbyopia correction, and minimally invasive SmartSight lenticule extraction.

SCHWIND was founded in 1958 as a successful one-stop ophthalmology supplier. In 1992, the company launched into the refractive corneal surgery space with its first serial laser system, the SCHWIND KERATOM, and the first eye was treated for myopia correction in South Korea the same year. By 1999, the company transitioned exclusively to laser eye surgery. The early pioneering achievements of SCHWIND included, for example, the serial implementation of a standardized passive eye tracker, the serial use of online pachymetry as a significant safety factor, and the development of the

corneal wavefront method to detect and correct even the smallest aberrations in the cornea.

In 2007, we developed the AMARIS, a 500-Hz excimer laser system. From that point on, we became the international technology leader in excimer laser systems for refractive corneal surgery. Later, we launched the 750-Hz AMARIS laser, followed by the 1,050-Hz AMARIS laser, which is the flagship of our successful excimer laser portfolio today.

Another key differentiator is that SCHWIND's diagnostic devices[†] seamlessly integrate into our laser environment and allow the transfer of objective treatment data to both the AMARIS and the ATOS. These include the SCHWIND MS-39, SCHWIND SIRIUS+, and SCHWIND PERAMIS.

CURRENT STATUS

Today, our company continues to be a technology leader in laser systems for refractive and therapeutic corneal surgery. We have developed, produced, and marketed a high-quality product portfolio that includes the SCHWIND AMARIS and ATOS. To date, more than 2,250 SCHWIND laser systems have been installed worldwide; two-thirds of these are the AMARIS.

Our focus remains completely on our customers. We see our customers as part of the SCHWIND family. We also feel a great obligation to help their patients gain excellent visual results and significant lifestyle improvements.

CONCLUSION

At SCHWIND, we pride ourselves on being innovative and agile. Our medium



size, 30-year tenure in corneal refractive surgery, and steadfast relationships with customers allow us to respond to market needs fast, nimbly integrating developments that can make a big difference for surgeons and their patients.

We are proud that we are one of the only companies that can offer our customers quality-built laser platforms for the complete range of laser vision correction procedures. We aim to continue integrating improvements, additional applications, and a larger product portfolio to support surgeons and enhance the user and patient experience, and we will continue to be flexible and responsive to individual customer needs.

Roughly 5% of patients with refractive errors undergo laser vision correction.¹ Even if we can realize our vision that most patients will see laser vision correction as a valuable alternative to glasses and contact lenses, I think as a company and as an industry we are succeeding. We are continuously working on innovative ideas that can help us to reach this goal and our patients to lead happier lives with better vision and quality of life. ■

1. Market Scope. 2021 Refractive Surgery Market Report: Global Analysis for 2020 to 2026. December 2021. Accessed August 31, 2022. <https://www.market-scope.com/pages/reports/294/2021-refractive-surgery-market-report-global-analysis-for-2020-to-2026-december-2021>

ROLF SCHWIND

- Founder, SCHWIND eye-tech-solutions, Kleinostheim, Germany
- Financial disclosure: Minority shareholder (SCHWIND eye-tech-solutions)

DOMENIC VON PLANTA

- CEO, SCHWIND eye-tech-solutions, Kleinostheim, Germany
- Financial disclosure: Minority shareholder (SCHWIND eye-tech-solutions)

Yesterday, Today, and Tomorrow: The Changing Face of Modern Refractive Surgery



SCHWIND stands at the center of it all.

BY JOHN MARSHALL, FMEDSCI, PHD, FRCPATH, FRCOPHTH(HONS)

I've been involved in the development of laser systems for more than 50 years. Much of my early work in the 1960s, funded by the Ministry of Defense, was done with the Royal Air Force to establish thresholds for laser damage to the retina. This resulted in me sitting on or chairing many committees around the world that were created to protect the public from optical radiation. It also led to me drafting many of the codes of practice for laser safety. Working with the International Committee of the Red Cross, I chaired a committee that led to a Geneva Convention banning the use of antipersonnel lasers and an address to the United Nations that emphasized the importance of this cause. My early studies resulted in my developing a fundamental understanding of all the mechanisms involved in the interactions between lasers and biological tissues and ultimately laid the groundwork for me to make contributions to the research and design of lasers for surgical purposes, specifically in ophthalmology. I introduced the world's first diode laser for treating retinal conditions, and I also hold the grandfather patents for refractive surgery and cofounded Summit Technology, which was the first laser company to obtain US FDA approval for laser refractive surgery.

THE START OF A HEALTHY COLLABORATION

My original patents were for broad beam laser systems that used an iris diaphragm to slowly increase or decrease the area of the beam falling on the cornea. Shortly after my patents, SCHWIND designed a laser system that used a

continuous belt with a series of holes to increase or decrease the size of the aperture (Figure 1). Rather than react with animosity or aggression, I worked in harmony with them to move the field of refractive surgery forward. Our healthy collaboration continues today.

In the early days of excimer laser technology, there were three major players: Summit Technology, Visx, and SCHWIND eye-tech-solutions. Initially, all procedures were PRK, which was performed on the subepithelial surface of the cornea. These procedures were extremely successful, but in the early days patients complained of pain related to removing the epithelium and some patients experienced mild disturbances of transparency or haze. New innovations led to the development of treatments that could be performed underneath a surgically lifted flap of stroma material. This procedure, termed LASIK, continues to be a successful procedure, but a subsequent version, laser epithelial

keratomileusis (LASEK), only enjoyed brief success.

SCHWIND led a second revolution, refocusing efforts of refractive correction back to the surface. It developed a totally new treatment, transepithelial PRK (Smart Surf^{ACE}), in which its AMARIS laser was fired through the intact epithelium. This was a far less painful procedure for patients, and it avoided all of the problems of biomechanics that are associated with LASIK. This helped make surface ablation a more attractive option once again.

BACKED BY GOOD SCIENCE

SCHWIND has always been an innovative company built on a solid foundation of strong science and phenomenal relationships with their customers. As a result, they can adapt quickly to clinical feedback to meet the needs of the surgical community. SCHWIND works together with clinicians to bring innovations through the industrial design and commercialization stages



Figure 1. The first SCHWIND laser used a continuous belt with a series of holes to increase or decrease the size of the aperture.



Figure 2. A timeline of innovation brought to the market by SCHWIND.

(Figure 2). In terms of laser eye surgery especially, this has been extremely important.

Until recently, all laser vision correction was accomplished through the removal of tissue by potentially weakening the mechanical structure of the cornea. But because the superficial stroma is the strongest part of the cornea, concerns about long-term biomechanical stability prompted some to consider alternative methods of refractive correction. One attempt involved preserving the superficial fibers but removed a piece from the deeper stroma.

The latest development in corneal refractive surgery is lenticule extraction, a minimally invasive procedure performed through small access incisions. SCHWIND is once again leading the way with its SmartSight procedure, performed with its ATOS femtosecond laser. During the procedure, the ATOS creates a predefined lenticule in the intrastromal corneal tissue and small peripheral incisions in the cornea through which the lenticule can be removed. There is no flap and no laser ablation, but it does affect the biomechanical strength of the system. Some patients are drawn to the lenticule extraction procedure because it is performed with a single laser system, resulting in a fast treatment time with high patient comfort. Current indications include myopia and astigmatism correction.

LOOKING AHEAD

The success of the lenticule extraction procedure has led to another innovative concept, which is stroma supplementation surgery. Rather than weakening the eye, like with other procedures, stroma supplementation strengthens the eye by insertion of a specially processed lenticule derived either from human or pig corneal stromal tissue. I am currently involved in developing a technique to extract the lenticules from pig corneas

and use them to reshape the human cornea. The shaped lens is made from natural pig stroma with all the spatial relationships of the collagen preserved but no cell and no antigens or antibodies. I believe this represents a breakthrough in the future of refractive surgery; for the first time, we have a procedure that achieves refractive correction while increasing biomechanics. I have no doubt that SCHWIND will once again be watching the advent of the procedure and leading the way in innovation.

Another element

that I consider will have a big impact on refractive surgery is our understanding of human genetics with respect to the cornea in general and to keratoconus and ectasia in particular. The potential ability to genetically identify people with atypical corneal biomechanics prior to surgery will be a major step forward in corneal refractive surgery. It will essentially help surgeons avoid postoperative corneal ectasia and other complications that have been seen in the past.

CONCLUSION

SCHWIND's surface ablation procedures and the speed with which it produces innovations are second to none. This is for two main reasons. First, the company has a great team of scientists, optical engineers, and other key personnel that keep up with the fast-paced innovation required in ophthalmology. Second, SCHWIND has a huge international family of customers. The company listens to what the customers need and quickly and efficiently brings innovations into the marketplace.

I've enjoyed a wonderful relationship with SCHWIND over the years. The company has had a great 30 years, but the best is certainly yet to come. ■

JOHN MARSHALL, FMedSci, PhD, FRCPath, FRCOPTH(HONS)

- Frost Professor of Ophthalmology and Chairman of the Academic Department of Ophthalmology, Kings College London at Saint Thomas' Hospital, United Kingdom
- marshall-eye@kcl.ac.uk
- Financial disclosure: None

Why We Choose to Be Part of the SCHWIND Family



The strength of the technology, its customer care, and the agility and speed of innovation make SCHWIND a great company to partner with.

BY CARMEN JOSÉ BARRAQUER COLL, MD; ÁNGELA MARÍA GUTIÉRREZ, MD; JESÚS VIDAURRI LEAL, MD; AND JOSÉ MIGUEL VARAS, MD

Carmen José Barraquer Coll, MD

I am a daughter of Professor José Ignacio Barraquer Moner, who is known to be the father of refractive surgery. I am among the fourth of five generations of ophthalmic surgeons in the Barraquer family. We run and work at the Barraquer Clinic in Bogotá, Colombia, where refractive surgery was developed. It is easy to understand why I became an eye doctor: Watching my father make great contributions to ophthalmology has been a beacon of light, guiding my way.

The Barraquer Clinic has been using SCHWIND lasers since 1995, first the SCHWIND KERATOM, then the SCHWIND ESIRIS, and currently the SCHWIND AMARIS 500. All of these laser systems have produced very good patient outcomes over the years. We have five anterior segment surgeons who perform refractive surgery in our institution; all have enjoyed operating with SCHWIND's laser systems. The number of refractive surgery procedures that we have collectively performed over the years is considerable. Although laser refractive surgery is an important part of our practice and procedural volume, in our minds, it is only one of many surgical procedures we perform as corneal and anterior segment surgeons to improve visual performance in our patients.

Today, I am the head of our clinic. I no longer perform surgery, but I continue teaching as a professor in our school of ophthalmology and see patients in the clinic. I also continue to enjoy a fruitful relationship with SCHWIND and its Latin American distribution partner, Rocol. Both provide outstanding service support. Over the past 45 years, I have witnessed many innovations in ophthalmology and refractive surgery. Today, I believe refractive surgery is in an unparalleled arena with much less risk of complications than what we saw in the beginnings of laser surgery. Patients all over the world achieve good results with quality laser systems and innovative technologies.

Ángela María Gutiérrez, MD

It's hard to believe that 30 years have passed since I was introduced to SCHWIND's technology. From the very beginning until now, my impression of the company is the same: SCHWIND cares deeply for its customers and sees us as an extension of their family. SCHWIND works very closely with surgeons—the

relationship we share is really special. When a surgeon has a valuable idea, the company is willing to support and collaborate with them to develop new innovations. I believe that there's nothing better than working with a company like SCHWIND because they truly support their surgeons and help us to treat our patients with the highest-quality technologies.

My initial experience with SCHWIND was with its first laser platform, the KERATOM. Immediately, I was impressed by the precision and postoperative surgical results. Additionally, patients were extremely happy with their outcomes and the experience they had in our clinic and with the laser.

This introduction to SCHWIND's offerings convinced us to focus on the company's technologies. With every new technology



Figure. The SCHWIND AMARIS laser platforms.

that was released, I continued to be impressed by SCHWIND. The SCHWIND AMARIS (Figure) is almost perfect. The results are excellent, and again patients are happy with their experience and their outcomes, which have shown to be stable in the long term.

I choose SCHWIND because of the outstanding technology, the excellent outcomes, and for the relationships they have with their customers.

Jesús Vidaurri Leal, MD

Schwind eye-tech-solutions has been a market leader since modern refractive surgery became a reality in the 1990s. At that time, I chose Schwind because I felt the company had the best and safest surgical technologies and techniques available. Three decades later, the same is still true. The refractive surgery team at Instituto Vidaurri de Ojos currently uses the SCHWIND AMARIS 1050 as well as the company's diagnostic equipment, including the Sirius, Peramis, and MS39. This completes our refractive surgery suite. We have performed more than 50,000 refractive surgery procedures (PRK, phototherapeutic keratectomy, LASIK, and femtosecond LASIK) in the past 30 years using SCHWIND technology in northeastern Mexico. Most importantly, Schwind technology has enabled us to perform these procedures with the highest degree of safety and success.

SCHWIND has always prioritized safety and precision. I think of the company and Rocol as our partners. Together, we have offered patients safe and effective solutions for their refractive problems for 3 decades. I am thankful to Rolf Schwind, who I consider a friend, and his beautiful family for the lifetime of work they have dedicated to advancing refractive surgery, allowing many of us around the world to change the lives of our patients.

The SCHWIND team is led by intelligent, humble, perfectionist, and visionary leaders who have worked since the beginning with the most brilliant minds in refractive surgery, including Professor

Barraquer, who recommended the first SCHWIND KERATOM laser to me in 1993 in a conference in Bordeaux, France, and Dr. Jenkins from the United Kingdom where I first witnessed this equipment in action. Their complete focus remains on bringing technology that works to the market, and they have never lost focus on safety and precision. Congratulations and many thanks to Mr. Schwind and the entire SCHWIND company for your lifelong dedication to pushing refractive surgery toward safer, more efficient, and more precise diagnostic and laser treatment technologies.

José Miguel Varas, MD

Keratotomy—the first iteration of corneal refractive surgery—was invented by Professor José Ignacio Barraquer in the 1940s. It was originally performed by manually carving a frozen sheet of cornea on a precision lathe. I had the honor of learning from Professor Barraquer during my residency. He showed me the technique, method, and calculations that were required to reshape the cornea to achieve a refractive correction.

Forty years later, in the 1990s, the first excimer laser systems for refractive surgery entered the marketplace. Once again, I turned to the master for advice and asked him to recommend the best instrument available for refractive surgery. His answer was the SCHWIND KERATOM. Professor Barraquer's advice was as accurate then as it had always been. I started using the KERATOM in 1994. After only a few short experiences with the system, I was convinced that the SCHWIND technology was the best of all.

The laser's rotation of fractal masks allowed the correction of all types of myopia, hyperopia, and astigmatism with great precision and elegance. There were limits of magnitude—as to be expected with any new technology—but they were defined in the first few years, thanks to the exceptional contributions of many of SCHWIND's researchers, engineers, and scientists—of course in collaboration with key surgeons.

In 2002, my practice acquired the SCHWIND ESIRIS flying spot laser. The auto-tracking technology simplified the laser and made it easier to use less energy during the treatments. In 2011, we acquired the SCHWIND AMARIS, which opened the door to new elements of precision and speed of treatment.

SCHWIND is a reliable company that is responsive to its users' needs. The quality of its products is unparalleled. Additionally, SCHWIND works closely with its distributors and offers advice to and alliance with its users through social gatherings, congresses, user meetings, and visits to their laboratories.

My institution does not focus on the volume of patients we see but on the careful analysis of the indications and calculations required to obtain the best refractive results. I estimate that, in 28 years of practice, we have operated on more than 25,000 patients, many with SCHWIND's technologies and innovations. ■

CARMEN JOSÉ BARRAQUER COLL, MD

- Professor of Ophthalmology and Head, Clínica Barraquer, Bogotá, Colombia
- cb@barraquer.com
- Financial disclosure: None acknowledged

ÁNGELA MARÍA GUTIÉRREZ, MD

- Clínica Barraquer, Bogotá, Colombia
- angutierrez@tutopia.com
- Financial disclosure: None acknowledged

JOSÉ MIGUEL VARAS, MD

- Refractive, Cornea, and Cataract Surgeon, Centro Oftalmico Varas Samaniego, Guayaquil, Ecuador
- jmvaras43@me.com
- Financial disclosure: None

JESÚS VIDAURRI LEAL, MD

- Medical Director, Instituto Vidaurri de Ojos, Monterrey, Mexico
- Professor of Ophthalmology and Chairman, Universidad de Tamaulipas
- Financial disclosure: None acknowledged

Wide Corneal Epithelial Mapping Using OCT



Controlling the thickness, shape, and growth of the corneal epithelium can minimize the risk of regression.

BY JERRY TAN, MBBS(S'PORE), FRCS(EDIN), FRCOPHTH, FAMS

Since the introduction of laser vision correction (LVC)¹ in the form of PRK,² LASIK,³ or refractive lenticular extraction,⁴ the stability and persistence of the correction have been a matter of controversy and debate.⁵ Refractive regression is the term used to describe the loss of the effect of LVC. Regression results in the postoperative refraction deteriorating toward the initial refraction. Although there have been attempts to distinguish topographic/corneal regression (ie, the modified corneal curvature returning toward its preoperative curvature) from refractive progression (ie, the refraction changes due to continued axial length elongation),⁶ there has been no standardized and universally adopted method to document or study this. Axial length measurement is presently extremely accurate but rarely performed for patients who undergo LVC.

Topographic regression has been often associated with changes in the morphology of the epithelium induced by the alteration in curvature imposed on the underlying change in the stroma as a result of the LVC.^{7,8}

Studies have shown that PRK,⁹ LASIK,¹⁰ and SMILE (Carl Zeiss Meditec)¹¹ are all affected (to different degrees) by the induced epithelial morphological change, most commonly hyperplasia, leading to true topographic regression.

With the advent and refinement of OCT technologies, anterior segment OCT devices have immensely improved the visualization of the corneal epithelium. They have also helped with our understanding of the role the epithelium plays in corneal-induced

regression. The device used in the SCHWIND platform is the SCHWIND MS-39,[†] which incorporates the latest in OCT technology and is combined with the well-established Placido-based topography system (Figure 1). The unique combination makes the SCHWIND MS-39 currently the most advanced diagnostic workstation for corneal work.

OCT tomographers have a much better resolution and signal-to-noise ratio when compared to Scheimpflug scanning slit tomographers. The SCHWIND MS-39 has unprecedented capabilities in 3D imaging of the epithelial thickness (Figures 2 and 3) without the

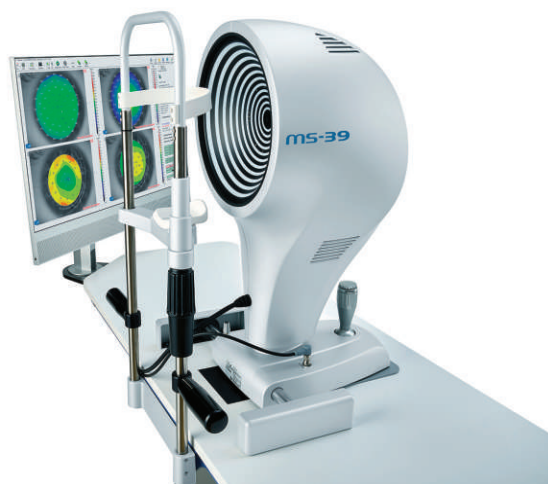

Figure 1. The SCHWIND MS-39.

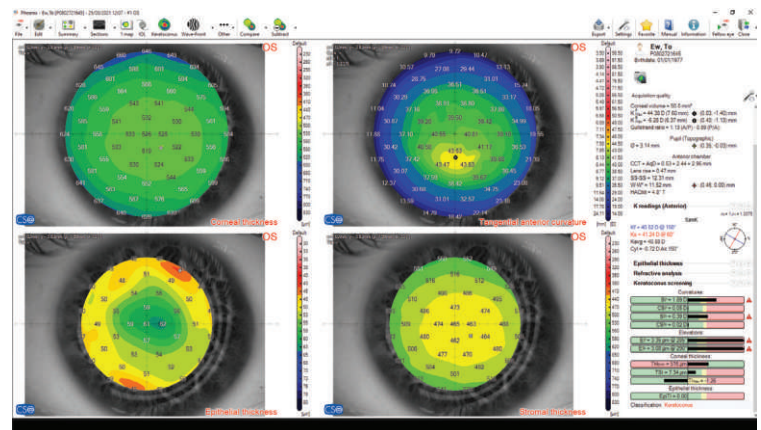


Figure 2. Combination of corneal topography and corneal thickness measurements for both stroma and epithelium.

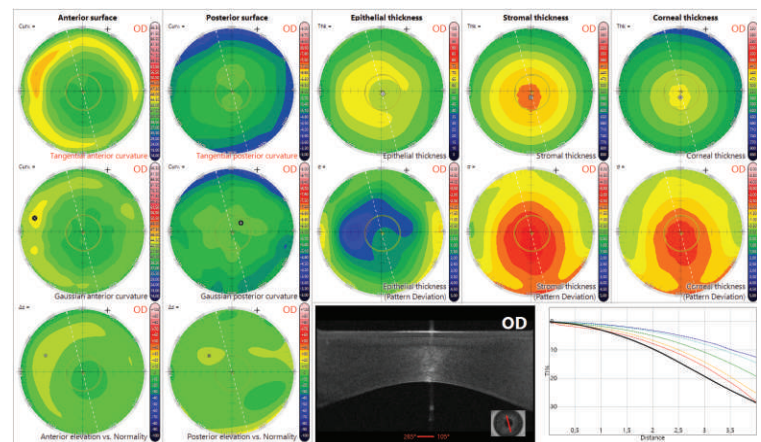


Figure 3. Combination of corneal topography (anterior and posterior cornea) with pattern deviation of corneal stroma and epithelial thickness.

[†]Manufactured by CSO SRL

"The corneal epithelium is one of the final frontiers of LVC surgery. Controlling its thickness, shape, and growth will make LVC more accurate by minimizing the risk of regression."

cumbersome ultrasound water bath system. It is easily comparable to the very high frequency ultrasound system. One of the most important features it has is the ability to measure a widefield epithelial map precisely, easily, and quickly.

The short- and long-term stability of LVC has been questioned in the past.¹² In particular, PRK seems to be associated with an overshoot followed by a reduction of the overcorrection toward the so-called final refraction.¹³ This has been considered as part of the procedure. It is the weakness of the PRK procedure when compared to LASIK or lenticule extraction with either SMILE or SmartSight (SCHWIND eye-tech-solutions) in which the so-called final refraction is achieved more rapidly.¹⁴ It is the same for hyperopic and myopic correction with hyperopic PRK having the longest recovery time.

There are only a few studies trying to distinguish topographic regression from refractive progression.¹⁵ Results from these studies show that the epithelium is responsible for short- to mid-term changes at the anterior corneal surface.⁹ Epithelial hyperplasia can occur in all forms of LVC.^{16,17}

A study of transepithelial PRK (TransPRK) demonstrated essentially no epithelial thickening at 1-month follow-up.¹⁸ Another study using the same LVC platform found that thinner corneal epithelium tended to thicken more after TransPRK. Additionally, patients with preoperatively thicker epithelium tended to thin after TransPRK.¹⁹

Surface ablation induces corneal surface roughness due to laser spot size and other factors.²⁰⁻²² This postoperative irregularity

elicits an epithelial response that smooths the corneal surface.²³ The regrowth of the epithelium compensates for corneal shape modifications. It also lowers the laser-induced irregularities and overall corneal aberrations.²⁴

Huang et al showed that epithelial thickness modulations after ablation can be modeled mathematically to explain clinically observed regression and induction of aberrations.²⁵ A smooth stromal bed²⁶ after the ablation combined with a large optical zone²⁷ and a wide transition zone²⁸ produces less remodeling of the epithelium. The prophylactic use of CXL has also been proposed to arrest the effects of epithelial remodeling.²⁹

The epithelial refractive power alone is an average of 1.03 D (range, 0.55–1.85 D) over the central 2-mm zone and 0.85 D (range, 0.29–1.60 D) at the 3.6-mm zone.³⁰ Other reports found lower values for the optical power of the epithelium.³¹

CONCLUSION

The role of the corneal epithelium in the corneal net power and thus total ocular refraction is gaining more importance. The corneal epithelium is one of the final frontiers of LVC surgery. Controlling its thickness, shape, and growth will make LVC more accurate by minimizing the risk of regression. ■

1. Marshall J, Trokel S, Rothery S, Krueger RR. A comparative study of corneal incisions induced by diamond and steel knives and two ultraviolet radiations from an excimer laser. *Br J Ophthalmol*. 1986;70(7):482-501.
2. Munnerlyn CR, Koons SJ, Marshall J. Photorefractive keratectomy: a technique for laser refractive surgery. *J Cataract Refract Surg*. 1988;14(1):46-52.
3. Buratto L, Ferrari M. Excimer laser intrastromal keratomileusis: case reports. *J Cataract Refract Surg*. 1992;18(1):37-41.
4. Shah R, Shah S, Sengupta S. Results of small incision lenticule extraction: all-in-one femtosecond laser refractive surgery. *J Cataract Refract Surg*. 2011;37(1):127-137.
5. Ficker LA, Bates AK, Steele AD. Excimer laser photorefractive keratectomy for myopia: 12 month follow-up. *Eye (Lond)*. 1993;7(5):617-624.
6. Seiler T, Holschbach A, Derse M, Jean B, Genth U. Complications of myopic photorefractive keratectomy with the excimer laser. *Ophthalmology*. 1994;101(1):153-160.
7. Lohmann CP, Güell JL. Regression after LASIK for the treatment of myopia: the role of the corneal epithelium. *Semin Ophthalmol*. 1998;13(2):79-82.
8. Reinstein DZ, Archer TJ, Gobbe M. Rate of change of curvature of the corneal stromal surface drives epithelial compensatory changes and remodeling. *J Refract Surg*. 2014;30(12):799-802.
9. Sedaghat MR, Momeni-Moghadam H, Gazanchian M, et al. Corneal epithelial thickness mapping after photorefractive keratectomy for myopia. *J Refract Surg*. 2019;35(10):632-641.
10. Spadea L, Fasciani R, Necozone S, Balestrazzi E. Role of the corneal epithelium in refractive changes following laser in situ keratomileusis for high myopia. *J Refract Surg*. 2000;16(2):133-139.
11. Reinstein DZ, Archer TJ, Bogge M. Lenticule thickness readout for small incision lenticule extraction compared to artemis three-dimensional very high-frequency digital ultrasound stromal measurements. *J Refract Surg*. 2014;30(5):304-309.
12. Kato N, Toda I, Hori-Komai Y, Sakai C, Tsubota K. Five-year outcome of LASIK for myopia. *Ophthalmology*. 2008;115(5):839-844.e2.
13. el-Agha MS, Johnston EW, Bowman RW, Cavanagh HD, McCulley JP. Excimer laser treatment of spherical hyperopia: PRK or LASIK? *Trans Am Ophthalmol Soc*. 2000;98:59-66; discussion 66-69.
14. Spadea L, Sabetti L, D'Alessandri L, Balestrazzi E. Photorefractive keratectomy and LASIK for the correction of hyperopia: 2-year follow-up. *J Refract Surg*. 2006;22(2):131-136.
15. Wilson SE, Klyce SD, McDonald MB, Liu JC, Kaufman HE. Changes in corneal topography after excimer laser photorefractive keratectomy for myopia. *Ophthalmology*. 1991;98(9):1338-1347.
16. Kanellopoulos AI. Comparison of corneal epithelial remodeling over 2 years in LASIK versus SMILE: a contralateral eye study. *Cornea*. 2019;38(3):290-296.
17. Ryu IH, Kim BJ, Lee JH, Kim SW. Comparison of corneal epithelial remodeling after femtosecond laser-assisted LASIK and small incision lenticule extraction (SMILE). *J Refract Surg*. 2017;33(4):250-256.
18. Kaluzny BI, Szkulimowski M, Bukowska DM, Wojtkowski M. Spectral OCT with speckle contrast reduction for evaluation of the healing process after PRK and transepithelial PRK. *Biomed Opt Express*. 2014;5(4):1089-1098.
19. Jun I, Kang DSY, Arba-Mosquera S, Kim EK, Seo KY, Kim TI. Clinical outcomes of transepithelial photorefractive keratectomy according to epithelial thickness. *J Refract Surg*. 2018;34(6):533-540.
20. Netto MV, Mohan RR, Sinha S, Sharma A, Dupps W, Wilson SE. Stromal haze, myo broblasts, and surface irregularity after PRK. *Exp Eye Res*. 2006;82:788-797.
21. Vinciguerra P, Azzolini M, Airaghi N, Radice P, De Molfetta V. Effect of decreasing surface and interface irregularities after photorefractive keratectomy and laser in situ keratomileusis on optical and functional outcomes. *J Refract Surg*. 1998;14(2 suppl):S199-S203.
22. Vinciguerra P, Azzolini M, Radice P, Sborgia M, De Molfetta V. A method for examining surface and interface irregularities after photorefractive keratectomy and laser in situ keratomileusis: predictor of optical and functional outcomes. *J Refract Surg*. 1998;14(suppl 2):S204-S206.
23. Fantes FE, Waring GO 3rd. Effect of excimer laser radiant exposure on uniformity of ablated corneal surface. *Lasers Surg Med*. 1989;9(6):533-542.
24. Reinstein DZ, Archer TJ, Gobbe M. Improved effectiveness of transepithelial PKT versus topography-guided ablation for stromal irregularities masked by epithelial compensation. *J Refract Surg*. 2013;29(8):526-533.
25. Huang D, Tang M, Shekhar R. Mathematical model of corneal surface smoothing after laser refractive surgery. *Am J Ophthalmol*. 2003;135:267-278.
26. Aslanides IM, Kymionis GD. Trans advanced surface laser ablation (TransPRK) outcomes using SmartPulseTechnology. *Cont Lens Anterior Eye*. 2017;40(1):42-46.
27. Kaluzny BI, Piotrowiak-Slupska I, Kaszuba-Modrzejewska M, Stachura J, Arba-Mosquera S, Verma S. Three-year outcomes after high hyperopia correction using photorefractive keratectomy with a large ablation zone. *Br J Ophthalmol*. 2019;103(6):849-854.
28. Gauthier-Fournet L, Penin F, Arba Mosquera S. Six-month outcomes after high hyperopia correction using laser-assisted in situ keratomileusis with a large ablation zone. *Cornea*. 2019;38(9):1147-1153.
29. Kanellopoulos AI, Asimellis G. Epithelial remodeling after femtosecond laser-assisted high myopic LASIK: comparison of stand-alone with LASIK combined with prophylactic high-fluence cross-linking. *Cornea*. 2014;33(5):463-469.
30. Simon G, Ren Q, Kerwick GN, Parel JM. Optics of the corneal epithelium. *Refract Corneal Surg*. 1993;9:42-50.
31. Salah-Mabed I, Saad A, Gatinel D. Topography of the corneal epithelium and Bowman layer in low to moderately myopic eyes. *J Cataract Refract Surg*. 2016;42(8):1190-1197.

- JERRY TAN, MBBS(S'PORE), FRCS(EDIN), FRCOPHTH, FAMS**
 ■ Consultant Ophthalmologist, Jerry Tan Eye Surgery, Singapore
 ■ jtaneyes@singnet.com.sg
 ■ Financial disclosure: Consultant (Schwind eye-tech-solutions)

ATOS and SmartSight: Current Trends and Procedural Volume



A summary of outcomes from different clinics.

BY MAJA BOHAC, MD, PHD; VICTOR DERHARTUNIAN, MD; KISHORE RAJ PRADHAN, MD; AND IVAN GABRIĆ, MD

There are many laser vision correction (LVC) options available today, including a variety of lenticule extraction procedures, that expand the reach of refractive correction and increase the potential for patient satisfaction after surgery. Over the past decade, lenticule extraction has established itself as a viable alternative to LASIK and PRK for corneal refractive surgery. Lenticule extraction procedures, such as SmartSight (SCHWIND eye-tech-solutions), are an established LVC technique.

During the SmartSight procedure, the SCHWIND ATOS femtosecond laser, a platform designed to enable corneal cuts for a variety of indications, is used to create a predefined lenticule in the intrastromal tissue of the cornea and make small peripheral incisions in the topmost layer of the cornea for lenticular access. The procedure spares tissue by optimizing lenticular geometry. No lenticule sidecut is performed, and the lenticule is tapered outside the optical zone using a transition zone, much like with the SCHWIND AMARIS, toward the periphery to reduce epithelial remodeling and minimize regression.

Tight nomograms are possible with ATOS, decreasing the risk for undercorrection in either sphere or cylinder. The laser boasts fast cutting times, a compact design, static cyclotorsion compensation imported from the SCHWIND SIRIUS scheinpflug system[†], pupil recognition, objective treatment offset, and cyclotorsion correction during and after the docking procedure.

This article details the clinical experience from three centers that have been using the ATOS since 2020: Matrika Eye Center in Kathmandu, Nepal; Svjetlost Clinic in Zagreb, Croatia; and EyeLaser in Vienna, Austria. Our practices were among the first in the world to use the ATOS femtosecond laser for both LASIK and lenticule extraction procedures.

Collectively, as of July 2022, we have created more than 1,000 flaps and more than 1,000 SmartSight lenticules.

The outcomes with this new laser are promising and, in our opinion, point to a paradigm shift in refractive correction. In our experiences, the platform is helping to build a renaissance in corneal refractive surgery. For us to be involved with a technology so early in its lifecycle has been exciting.

LOWER LASER POWER

We use similar settings. Pulse energy ranges from 80 to 90 nJ, and spot and track distances range from 4 to 5 μm and 2.5 to 3.5 μm , respectively. These settings lead to an overall treatment dose of 0.8 J/cm² or less.

Lenticules can be created with an energy level as low as 75 nJ per pulse (with tighter spacing) or with a track distance as large as 5 μm using higher energy per pulse. Oversizing the cap so that it is approximately 0.8 mm wider than the transition zone provides ample room for surgical maneuvers. The overall cap diameter ranges from 8.0 to 8.6 mm.

ADVANTAGES

The use of lower laser power levels at higher repetition rates. This can result in a more accurate treatment and cyclotorsion control during surgery, which can improve astigmatism correction and decrease vertical coma. The ATOS also creates a refractive transition zone at the edge of the lenticule, possibly improving quality of vision. Because the lenticule has a zero-thickness edge, it is easier to extract without leaving lenticule fragments behind and requires no minimum lenticule thickness.

Docking. Docking with the ATOS is seamless. This is key: A successful dock promotes successful surgery and the best chance for excellent postoperative outcomes. The

docking process with ATOS is gentle, and there is no blackout phase, promoting a better patient experience and easing patient fears.

Eye tracker-guided centration and docking.

We feel the biggest advantage of the ATOS compared to competing devices is the eye tracking and cyclotorsion compensation, which makes sure you are treating on the right axis. The eye tracker provides the operator with a coaxial view through the cone of the patient interface. It includes static overlays of the target pupil position surrounded by two concentric hot zones (target hot zone of 200 μm radius; maximum permissible hot zone of 700 μm radius; Figure). Once the patient is instructed to move the operating table, the operator centers the interface on the target pupil position, which is detected by a video-based eye tracker. Suction is then applied and pupil centration is confirmed to be in the target hot zone. A maximum permissible hot zone is also shown

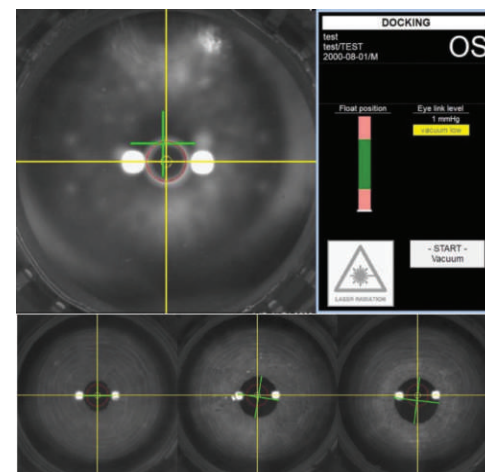


Figure. Static overlays of the target pupil position (yellow crosshairs) surrounded by two concentric hot zones (target hot zone of 200 μm radius, marked as a yellow circle; maximum permissible hot zone of 700 μm radius, marked as a red circle). The torsional deviation is displayed by the rotated green crosshairs.

on the display (the red circle in the Figure). If the pupil is not in either zone, docking is reattempted.

The last valid laser eye-tracker video frame is used for cyclotorsion control, and the torsional misalignment from the diagnostic image is determined and accounted for by the torsional deviation display (the green crosshairs in the Figure).

Astigmatism correction. The ATOS can potentially treat higher amounts of astigmatism with better precision than other femtosecond laser platforms. The device's built-in torsion control compensates for rotation during the docking procedure. In our experience, results with SmartSight for astigmatism correction are excellent. We have also found that refractive correction with SmartSight is comparable to LASIK with less chance for regression.

Lenticule dissection and extraction. With ATOS, the edge of the lenticule is zero-thickness. This simplifies lenticule dissection and extraction on the periphery.

OUTCOMES

ATOS performance for LASIK and SmartSight is very good. Once the right settings for the device have been found, users may slightly refine their technique, and results are very convincing.

For flap creation. None of us experienced a long learning curve for flap creation with the ATOS. In fact, it was nearly nonexistent thanks to the intuitive user interface of the device, allowing us to dock the patient interface and achieve the same efficiency in flap creation as we had after years of experience with other femtosecond laser platforms. This was true regardless of the surgeons' level of experience. After five or six procedures, all surgeons were able to complete the flap in just a few minutes.

The day 1 postoperative results with ATOS are impressive. The flap edge is smooth, similar to the quality achieved with a microKERATOM, and there is minimal to no inflammation. This is because of the low energy dose (and total energy) being delivered to the corneal lamella. Further, ATOS allows granular customization, including spot/track distances and energy fine-tuning, so that each surgeon can determine their own settings.

With ATOS, it is possible to fine-tune the energy to ensure that every flap is easy to dissect. The level of adjustment is virtually infinite.

For SmartSight. All surgeons were comfortable performing SmartSight within a few weeks of experience with the ATOS. After a few lenticules, even the less-experienced surgeons felt secure enough to perform the procedure independently. SmartSight feels easy to perform almost instantaneously due to the device's torsion control, eye tracking, pupil recognition/centration, and positioning technologies.

It is typical for patients who undergo SmartSight to experience about 90% to 95% visual recovery on the first day postoperatively. The smoothness of the bed makes visual recovery faster than any other laser system, and the different lenticule shape and composure requires less tissue removal. This is valuable in higher prescriptions. Contrast sensitivity may fluctuate within the first month.

Results with SmartSight have changed the outlook of lenticular surgery. It is becoming a procedure we perform more often, and we believe that lenticular surgery will become the procedure of the future.

Previously with lenticular surgery procedures, it took longer for patients to recover, and they did not see 20/20 or better on postoperative day 1. The *wow* factor was missing, and patients' vision was hazy and blurry immediately postoperatively. With SmartSight, however, the time commitment of surgery and the postoperative day 1 results are comparable to femtosecond LASIK. In our opinion, this is an important point for the evolution of the procedure. Patients can experience the same *wow* factor as after LASIK with a fast visual recovery and minimal risk of inducing or exacerbating dry eye disease. Additionally, after SmartSight, patients are not bound by any safety limitations for their daily activities.

The difference in central epithelial thickness at 12 months postoperatively from preoperative baseline has little to no correlation with the refractive power of the correction. On average, the thickness of the central epithelium increased by about 3 μm , with maximum changes of 12 μm thicker to 6 μm thinner compared to the preoperative baseline. Most

of the data points suggest a minimum change in central epithelial thickness between zero and 5 μm (see Figure 2 in the next article, "Enhancements to Lenticule Extraction").

COMPLICATIONS

In our experience, there are no known complications that are unique to ATOS. An opaque bubble layer can occur regularly, whereas black spots occur more rarely, and areas of inaccurate laser pulse placement due to eye movement are seldom.

Specifically for SmartSight, in some treatments initially the posterior plane was entered. Generally, it was detected by the surgeon and the anterior plane was subsequently entered.

CONCLUSION

One of our jobs as surgeons is to individualize treatment plans for our patients, ensuring not only the best postoperative outcomes but also meeting their needs. An adjustable laser system like the ATOS increases the range of patients we can treat, such as those with large pupils, thin corneas, and dry eyes. In our opinion, the clinical results we have achieved with the ATOS support the expanded use of the laser for LASIK flaps and SmartSight lenticule extraction. ■

MAJA BOHAC, MD, PHD

- Assistant Professor, Svjetlost Eye Clinic, Zagreb, Croatia
- maja.bohac@svjetlost.hr
- Financial disclosure: None

VICTOR DERHARTUNIAN, MD

- EyeLaser, Vienna, Austria; Warsaw, Poland; and Zurich, Switzerland
- SwissLaser, Warsaw, Poland
- vd@eyelaser.at
- Financial disclosure: None acknowledged

IVAN GABRIĆ, MD

- Svjetlost Eye Clinic, Zagreb, Croatia
- ivan.gabric@svjetlost.hr
- Financial disclosure: None

KISHORE RAJ PRADHAN, MD

- Medical Director, Matrika Eye Care Center, Kathmandu, Nepal
- drkishoreraj@hotmail.com
- Financial disclosure: None acknowledged

Enhancements to Lenticule Extraction



Several innovative features of the ATOS laser system provide advantages.

BY SAMUEL ARBA MOSQUERA, MSc, PhD

SCHWIND ATOS is a new development in femtosecond laser technology that enables the generation of LASIK flaps and lenticules for SmartSight lenticule extraction. It received the CE Mark in July 2020, early in the COVID-19 pandemic. Since then, a steadily growing number of surgeons in and beyond Europe has performed SmartSight. In all treated patients, lenticule removal was reported to be performed without relevant intraoperative complications.

SCHWIND ATOS works in the plasma-mediated ablation range, which is well below the photodisruption range and slightly above the threshold for laser-induced optical breakdown. It generates only low-density plasma and pulses in the low-energy range, providing a gentle, tissue-friendly treatment. Most procedures are performed using pulse energies between 75 and 100 nJ with spot/track spacings from 2.5 to 5 µm. ATOS does not require a minimum lenticule thickness, potentially reducing the overall thickness of the lenticules.

FEATURES AND ASSOCIATED ADVANTAGES

The basic features of the SCHWIND ATOS and their associated advantages (Table) have enabled the development of tight nomograms, no perceived undercorrections for either sphere or cylinder, and fast cutting times. The compact system includes cyclotorsion compensation imported from SCHWIND diagnostic devices (SCHWIND SIRIUS+, SCHWIND PERAMIS, and SCHWIND MS-39)[†], pupil recognition software, and objective treatment offset and cyclotorsion compensation during and after the docking procedure.

Compared to other lenticule extraction laser procedures and unlike excimer laser-based ablations, there is only a slight difference in cutting times depending

on the planned correction. With the SCHWIND ATOS, flaps can be cut in about 8 to 10 seconds and lenticules in about 15 to 18 seconds.

SCHWIND's application team accompanies surgeons on their first days of treatment in the clinic to support ATOS users as best as possible. The feedback from

the ever-growing SCHWIND ATOS user family is that the flap edges are very clean, but they can require attention to separate them cleanly in a single pass. Users also have commented that the stromal bed is smooth and visual acuities on day 1 produce the typical "wow" effect patients experience after LASIK. Regarding lenticule creation,

TABLE. FEATURES AND ASSOCIATED ADVANTAGES OF SCHWIND ATOS

Feature	Advantages
Click and Go Patient Interface	Easy and straightforward to insert and use
Single Size Patient Interface	Reduces the complexity of logistics and storage
Low Suction (sub-300 mm Hg)	Less load on the cornea/eye
Low Load (sub-200 g)	Less load on the cornea/eye
Offset for the Treatments	Better positioning of the lenticule with respect to the visual axis
Eye Tracking-Guided Centration and Docking	Semi-automated centering of the eye Better positioning of the lenticule with respect to the visual axis Provide robust, accurate, and precise alignment of the eye to the system
Eye Registration From Diagnostic Images (SIRIUS)	Better positioning of the lenticule with respect to the eye
Static Cyclotorsion Compensation	Better positioning of the lenticule with respect to the meridional orientation (astigmatism axis)
No Minimum Lenticule Thickness, No Lenticule Sidecut	Possibly reduces the overall thickness of the lenticules True transition zone Less epithelial remodeling Less regression
Progressive Refractive Transition Zone	Possibly reduces the epithelial remodeling
High Repetition Rate (MHz)	Faster treatments or better resolution
Works Centrifugally	The most important part (ie, the center of the treatment) is completed first
Asymmetric Spacing	More homogeneous cuts with less pulse energy
Overbending of the Cap	Protects against slight decentrations
High Numerical Aperture	Excellent resolution
Low Pulse Energy (sub-100 nJ)	Excellent resolution Lower corneal reactions
Quasi Telecentric Optics	Same cutting quality for the whole cornea

[†]Manufactured by CSO SRL

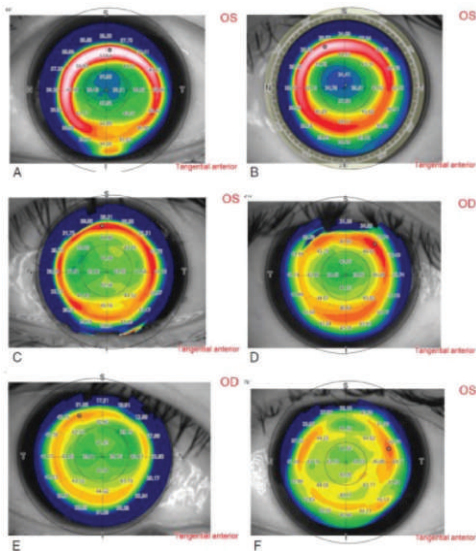


Figure 1. Postoperative day 1 topographies. In these cases, the planned optical zones were 6 mm.

users mentioned that lenticules may be unexpectedly easier to approach than flaps initially. The smoothness cannot be truly qualified in this setting because the pocket remains closed. Visual acuities on day 1 are good; on average, patients achieve 20/25 to 20/20 with a few exceptions of 20/32. Some even achieve 20/16.

On postoperative day 1, topographies look wide and clean and the planned optical zone is achieved (Figure 1). The optical zone for SmartSight lenticules can be up to 7.5 mm; overall lenticule diameters are larger due to the included transition zone. As the lenticules get thicker (eg, for higher corrections or larger optical zones), they are easier to extract, but less residual stroma is left behind. The ATOS limits the maximum lenticule thickness to between 25 and 165 μm . Further, ATOS imposes a minimum 275 μm calculated residual stromal thickness.

Extensive hyperplasia may be one reason why some competing lenticule systems require overplanning of the nomogram. The amount of epithelial hyperplasia appears to be much less with the ATOS than with competing technologies.¹ We believe that the use of a progressive refractive transition zone with the ATOS helps produce less hyperplasia, undercorrection, and regression and potentially reduces epithelial

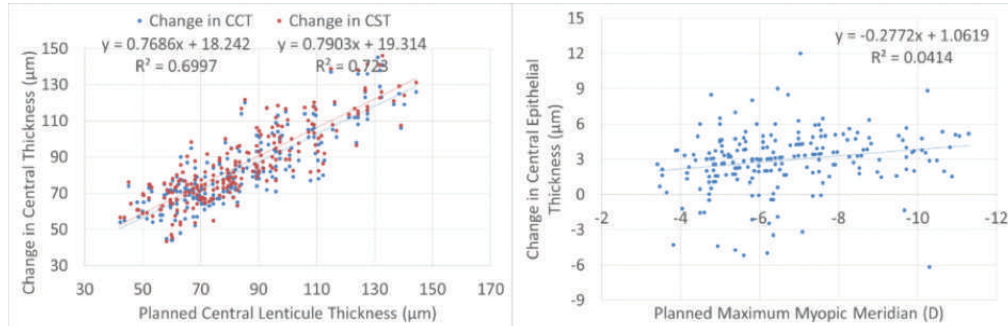


Figure 2. Change in central corneal thickness.

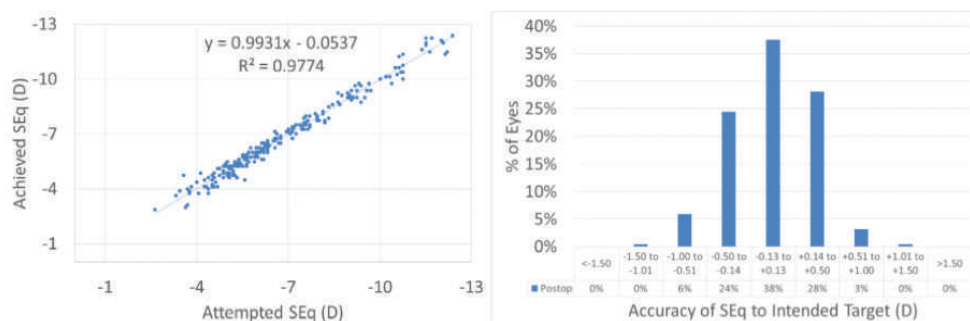


Figure 3. Accuracy of the spherical equivalent at 12 months postoperative.

remodeling. In one study, central epithelial thickening with ATOS was only $3 \pm 2 \mu\text{m}$ at 12 months (Figure 2).² Additionally, there were no reports of undercorrection for either sphere or cylinder and more than 90% of treatments were within ± 0.50 D of intended correction at the same time point (Figure 3).

The low pulse energy (sub-100 nJ) of the ATOS provides better resolution and reduces corneal reactions.³ The asymmetric spacings leads to more homogeneous cuts with less pulse energy. Additionally, a slight overbending of the cap is a protective measure against slight decentrations.

SMARTSIGHT OUTCOMES

Pradhan et al found that, at 12 months, 93% of eyes that underwent SmartSight achieved a UDVA of 20/20 or better.² In all eyes, UDVA remained within 1 line of the preoperative distance-corrected visual acuity (CDVA), and no eyes lost more than 1 line of CDVA. Refractive correction of the spherical equivalent (SEQ) and refractive astigmatism were both excellent, with 90% and 100% of eyes, respectively, within ± 0.50 D of

the target. In 89% of eyes, the axis of the refractive astigmatism was within 15° from the planned treatment.

Pradhan found that, for eyes with moderate to severe astigmatism (1.00 D or greater) preoperatively, 81% had 0.50 D or less of residual astigmatism postoperatively.⁴ The correlation between target-induced and surgically induced astigmatism for manifest refraction was relatively good, but it was lower than for SEQ. Almost all eyes (96%) showed an angle of error between -15° and $+15^\circ$.

There is a short learning curve with SmartSight lenticule extraction.⁵ In one study, the first 16 treatments were performed without astigmatism correction, followed by 52 treatments to optimize the laser's settings and refine the technique. Thereafter, the treatments (>100) have been performed with the optimized settings and technique. The UDVA outcomes are shown in Figure 4.

SmartSight does not yet have customized treatments. Data show that, above -5.00 D, 93% to 96% of eyes achieved a UDVA of 20/20 or at least equal to the preoperative CDVA.²

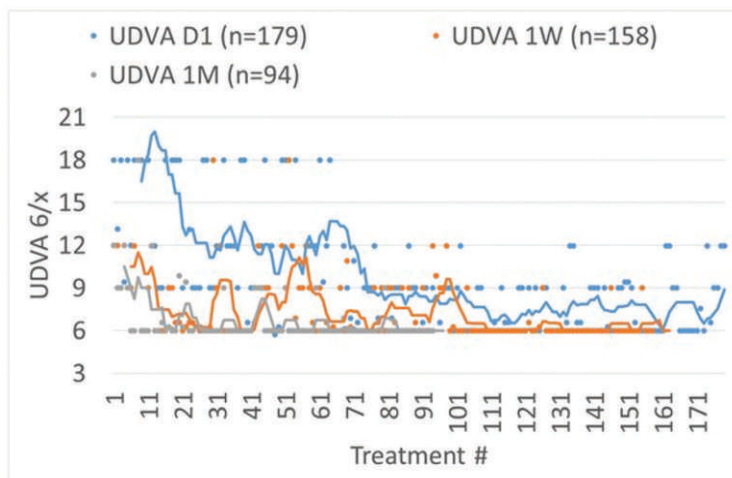


Figure 4. UDVA outcomes after SmartSight.

At ESCRS 2021, Maja Bohac, MD, PhD, reported that higher-order aberrations (HOAs) after SmartSight, especially spherical aberration and coma, remained essentially unchanged (Figure 5).⁶ Whole-eye ocular wavefront (OW) scans did not show changes from preoperative to 3 months postoperative for coma or spherical aberration, whereas HOA root mean square (RMS) increased by $0.14 \pm 0.15 \mu\text{m}$. Corneal wavefront (CW) measurements increased from preoperative to 3 months postoperative for coma ($0.22 \pm 0.21 \mu\text{m}$), spherical aberration ($0.17 \pm 0.19 \mu\text{m}$), and HOA RMS ($0.32 \pm 0.26 \mu\text{m}$). From preoperative to 3 months postoperative, HOAs changed for OW ($0.1 \pm 0.1 \mu\text{m}$), coma ($0.2 \pm 0.2 \mu\text{m}$), and spherical aberrations ($0.2 \pm 0.2 \mu\text{m}$) and HOA-RMS changed for CW ($0.3 \pm 0.3 \mu\text{m}$).

FUTURE OUTLOOK

In the future, the following advancements and features will be released for the SCHWIND ATOS:

- Easier flap transition;
- Conversion of a cap (lenticule) to a LASIK flap;
- Inclusion of intrastromal corneal ring segment function;
- Inclusion of a keratoplasty function; and
- Optimized centration with an asymmetric transition zone concept.

Furthermore, treatment options such as custom lenticules for myopia, hyperopic lenticules, and presbyopia-correcting lenticules are being considered to broaden the ATOS application range in the future.

CONCLUSION

The SmartSight lenticule extraction procedure will continue to undergo enhancements with the SCHWIND ATOS. The innovative laser system incorporates properties of the successful and proven SCHWIND AMARIS technology.

The ATOS works in an optimized but minimum pulse energy range and spaces the laser pulses asymmetrically. Of the many advantages, the eye tracking-guided centration and static cyclotorsion control seem to be relevant for the clinical success of the lenticule extraction procedure (ie, SmartSight in the SCHWIND nomenclature), paving the way for future customizations in lenticule profiles.

The concept for the SmartSight lenticule profiles were derived from the vast experience with the SCHWIND AMARIS and do not require any minimum thickness levels. The profiles incorporate a progressive refractive transition zone, possibly reducing the overall thickness of the lenticules and providing a true transition zone that causes less remodeling of the epithelium and less regression.

Both the current ATOS laser system and future developments can help surgeons stay on the cutting edge of laser vision correction. ■

1. Reinstein DZ, Archer TJ, Gobbe M. Lenticule thickness readout for small incision lenticule extraction compared to artemis three-dimensional very high-frequency digital ultrasound stromal measurements. *J Refract Surg.* 2014;30(5):304-309.
2. Pradhan KR, Arba Mosquera S. Twelve-month outcomes of a new refractive lenticular extraction procedure. *J Optom.* 2021;S1888-4296(21)00085-6.
3. Arba-Mosquera S, Naubereit P, Sobutas S, Verma S. Analytical optimization of the cutting efficiency for generic cavitation bubbles. *Biomed Opt Express.* 2021;12:3819-3835.
4. Pradhan KR, Arba Mosquera S. Three-month outcomes of myopic astigmatism correction with small incision guided human-cornea treatment. *J Refract Surg.* 2021;37(5):304-311.
5. Pradhan KR, Arba Mosquera S. Initial experience with the SCHWIND ATOS and SmartSight Lenticule Extraction. *J Clin Res Med.* 2020;3(4):1-5.
6. Bohac M. First European results of a new refractive lenticular extraction procedure - SmartSight by Schwind Eye Tech Solutions. Paper presented at the: ESCRS Annual Meeting; 2021.

SAMUEL ARBA MOSQUERA, MSC, PHD

- Optical/Visual Researcher, Biomedical Engineering Office, SCHWIND eye-tech-solutions, Kleinostheim, Germany
- samuel.arba.mosquera@eye-tech.net
- Financial disclosure: Employee (SCHWIND eye-tech-solutions)

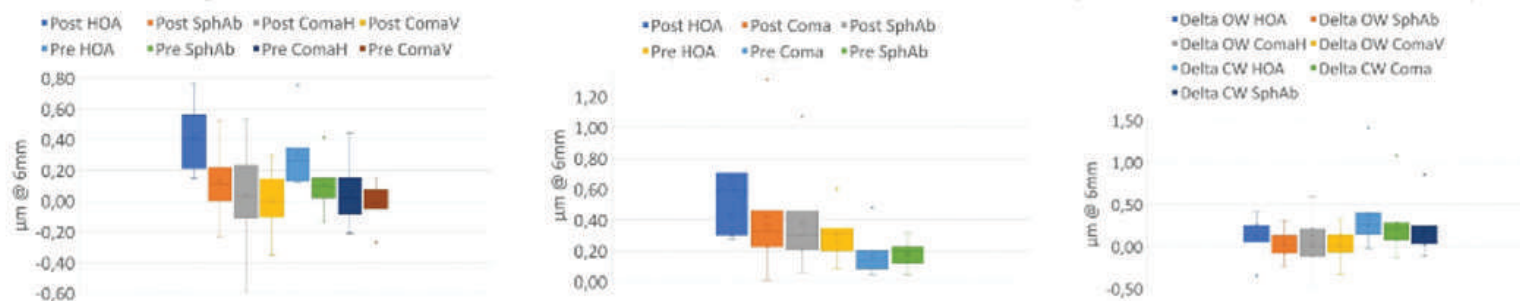


Figure 5. HOAs after SmartSight as measured by OW and CW.

PresbyMAX Monocular



Our surgical treatment of choice for presbyopia correction.

BY ALLON BARSAM, MD, MA, FRCOPHTH, AND DAVID KANG, MD

With the aging population, presbyopia is now the most common refractive error worldwide. In many parts of the developed world, it is therefore not uncommon for individuals to spend half of their lives with presbyopia. A variety of surgical approaches to presbyopia correction, including PresbyMAX with the SCHWIND AMARIS excimer laser family, are available, each with its own risks and benefits. This article explores how PresbyMAX can help patients achieve spectacle independence and insights into its role for presbyopia correction.

BACKGROUND

Visual acuity at different vergences is a common indicator for the depth of focus of spatial vision that is applied in clinical settings, such as in the form of defocus curves.¹ The impact of refractive error on visual acuity is well understood.² Recently, the impact of higher-order aberrations (HOAs) on visual acuity,³ particularly extended depth of focus, has become increasingly important.⁴

Presbyopia correction on the cornea has been historically associated with a loss of distance vision and contrast sensitivity, which can reduce quality of vision (at least in the short- to mid-term).⁵ This is presumably due to the induction of corneal aberrations to increase the range of focus (ROF) in operated eyes.⁶ The negative effects of corneal refractive surgery are higher for more aggressive presbyopia treatments that aim to provide functional vision with an increased ROF.⁷ This has led to the development of newer blended vision approaches⁸ and treatments with different aims in the ROF for distance and near eyes.⁹

The losses of distance vision and contrast sensitivity seem to be more evident

under monocular examining conditions and reduced under binocular vision conditions.¹⁰ This has led to the hypothesis that patients who have undergone monocular presbyopia treatment on the nondominant eye for distance may have better distance vision while retaining most of the gains in near vision compared to patients who have undergone bilateral presbyopia correction.¹¹

PRESBYMAX PROFILE FOR PRESBYOPIA CORRECTION

PresbyMAX uses an increased ROF profile for presbyopia correction¹² that works by creating a prolate corneal shape, controlling the induction of negative spherical aberration, and inducing a low amount of myopia.¹³ The distance refractive correction is applied over the entire optical zone and progressively becomes hyperprolate toward the center. This shape is influenced by the amount of addition; the higher the addition, the more powerful the center becomes.¹⁴

The PresbyMAX concept incorporates a residual myopic defocus in the near eye¹⁵ that can be altered to induce more or less myopia combined with lower or higher adds (ie, less or more induction of negative spherical aberration).¹⁶ Different versions of the profile are depicted in Figures 1 and 2, assuming emmetropia for distance vision in the distance-only aspheric optimization takes place and there is a hyperpositive central aspheric region. For near eyes, a residual myopic defocus is targeted.

Both of us have experience performing PresbyMAX monocularly to maintain distance vision and visual quality while enhancing intermediate and near vision in the near eye through the concept of increased ROF. The monocular profile for PresbyMAX involves correcting one eye

for distance vision using an aberration-free profile and correcting the contralateral eye with an increased ROF ablation. The ablation profile has been described elsewhere.¹⁷

When performed monocularly in the dominant eye, PresbyMAX is a more physiological approach than intraocular multifocality for the following reasons:

- It produces fewer negative effects for distance vision and visual quality;
- It allows patients to use any residual accommodative function in the natural lens to provide a more natural range of vision;
- It is possible to reverse the procedure;
- It is far less invasive than explanting or replacing an IOL; and
- If needed, spectacle correction can be used for night driving.

One of us (AB) determines the reading add preoperatively. Patients who require a reading add of +1.50 D or more receive a monocular PresbyMAX treatment whereas those who require lower amounts of add and who are happy to wear reading glasses for small print are treated with standard aberration-free monovision. For monocular PresbyMAX, a target refraction in the nondominant eye of -1.19 D is planned by adding +0.30 D to the refraction that is inputted into the laser (-0.89 D is the default in monocular PresbyMAX). An add value of +1.50 D is then selected and adjusted with an extra +0.05 D for every 1.00 D of myopia treated and +0.10 D is removed for every 1.00 D of hyperopia treated. An optical zone of 6.3 mm is selected for myopia and 6.5 mm for hyperopia and can be increased if needed in patients with large mesopic pupils to increase the ROF without losing too much quality of vision. Enhancement rates are low; this approach is a reliable tool for

total spectacle independence in patients with presbyopia.

Monocular PresbyMAX allows comparisons of pre- and postoperative findings and distance (nonpresbyopic) and increased ROF (presbyopic) corrections. In other words, due to the target myopic refraction, the attempted spherical correction for the near eye is more hyperopic whereas the cylindrical correction and the optical and total ablation zones are similar. This is also reflected in the attempted ablation depth, which is approximately 13 μm shallower in the near eye for myopia and, conversely, deeper for hyperopia.

PATIENT SELECTION AND POSTOPERATIVE RESULTS

Patients with incipient to frank presbyopia, usually between the ages of 40 and 60+ years old, are good candidates for a monocular PresbyMAX procedure. The intended anisometropia is properly reached for the distance and near eyes; however, the spread of postoperative spherical

equivalent is usually wider for the near eye. Astigmatism is equally corrected for both eyes. This demonstrates that the correction of astigmatism is largely independent from and not affected by the attempted increased ROF effect.¹⁸ The achieved BCVA should maximize visual acuity, and contrast at intermediate spatial frequencies should be maximized.

After monocular PresbyMAX, uncorrected distance visual acuity (UDVA) is an average of 3 lines better in the distance compared to the near eye. For the near eye, UDVA averages 20/40 to 20/32, with almost 50% of the near eyes reaching 20/32 or better. A binocular UDVA of 20/20 or better is achieved in almost all distance eyes, and a binocular uncorrected near visual acuity (UNVA) of J2 or better is achieved by virtually all eyes. This confirms the potential advantages of monocular presbyopic correction on the cornea.¹⁹

For a binocular defocus curve to increase the natural ROF of the visual system, at least four components are considered. The spherical refraction of either eye may

be different to provide better vision at two distances, and the increased ROF of either eye to extend the range around the nominal vergence may be different between eyes to provide sharper vision in a narrow range of distances or more functional vision in a wider range depending on the targeted amount of myopia and the PresbyMAX addition value the surgeon chooses. The combination of both eyes contributes to the achieved visual acuity at all distances; both eyes actively participate in the visual process to create binocular vision impressions.²⁰

BCVA is remarkably stable over the range of natural daylight pupil diameters after monocular PresbyMAX treatments. UCVA, however, depends heavily on pupil size in the case of blurred images. When a pinhole is placed in front of an ametropic eye, visual acuity can be increased drastically, even for considerable refractive errors, if the cause of ametropia lies in the optical pathway. This can be explained by the reduction of the blur circle area, which is proportional to the area of the pupil and drastically

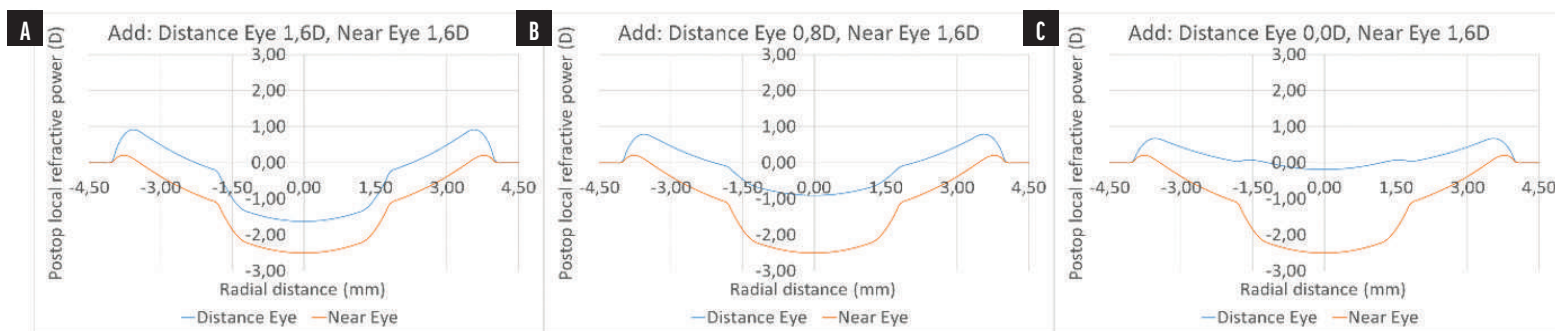


Figure 1. The relative addition in the distance eye is reduced from 100% (m-monovision; A) to 50% (hybrid; B) and 0% (monocular; C) with respect to the near eye.

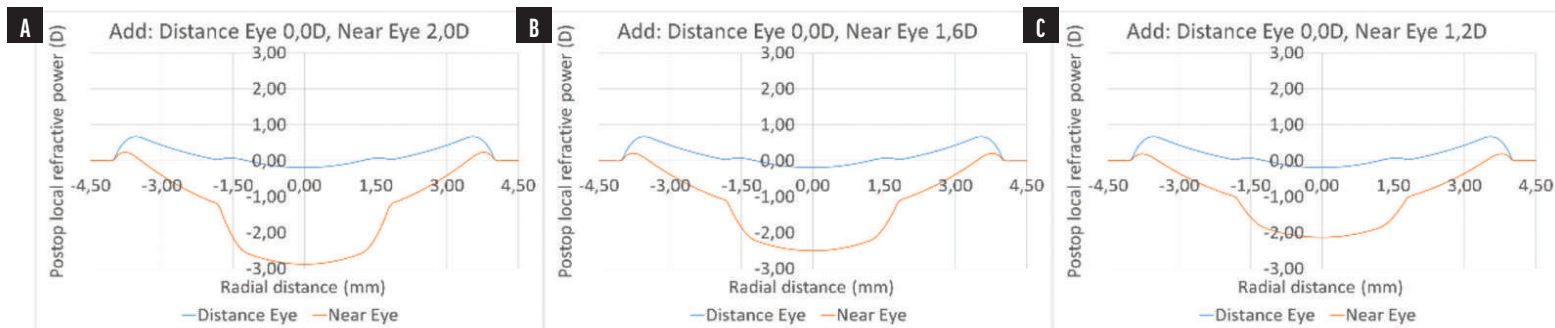


Figure 2. The presbyopic concept incorporates a residual defocus of -0.89 D in the near eye, which can be altered to induce more or less myopia combined with lower or higher adds (less or more induction of negative spherical aberration). For the near eye, the addition is reduced from 2.00 D (A) to 1.60 D (B) to 1.20 D (C).

reduced by a small pinhole.²¹ However, the maximal visual acuity achieved with a pinhole is bounded by diffraction effects and falls short of the visual acuity rendered by the best correction with natural pupil diameters.²²

With monocular PresbyMAX, corneal aberrations are not induced in the distance eye. There is, however, a slight induction of negative spherical aberration in the near eye with a mild postoperative difference of 0.20 D between eyes.

Correlations between the induced corneal spherical aberration (the treatment driver for increasing the ROF) with the refractive parameters show that about -0.10 D of corneal spherical aberration is induced per 1.00 D of planned addition. The correlation between the efficacy in the near eye and the refractive parameters shows that about 3 lines of UDVA (with respect to preoperative CDVA) are lost per 1.00 D of residual myopic refraction, combined with about 1 line of UDVA loss per 1.00 D of induced negative corneal spherical aberration.

CONCLUSION

Monocular presbyopia correction on the cornea with PresbyMAX can provide

excellent monocular and binocular uncorrected distance visual acuity in the distance eye and very good binocular UNVA and monocular UNVA in the near eye.

This represents an advantage for distance vision compared to patients receiving the presbyopic treatment binocularly. ■

1. Post CT Jr. Comparison of depth of focus and low-contrast acuities for monofocal versus multifocal intraocular lens patients at 1 year. *Ophthalmology*. 1992;99(11):1658-1663.
2. Rubin A, Harris WF. Closed surfaces of constant visual acuity in symmetric dioptric power space. *Optom Vis Sci*. 2001;78(10):744-753.
3. Williams D, Yoon GY, Porter J, Guirao A, Hofer H, Cox I. Visual benefit of correcting higher order aberrations of the eye. *J Refract Surg*. 2000;16(5):S554-S559.
4. Rocha KM, Vabre L, Chateau N, Krueger RR. Expanding depth of focus by modifying higher-order aberrations induced by an adaptive optics visual simulator. *J Cataract Refract Surg*. 2009;35(11):1885-1892.
5. Kohonen T, Böhm M, Herzog M, Hemkepler E, Petermann K, Lwowski K. Near visual acuity and patient-reported outcomes in presbyopic patients after bilateral multifocal aspheric laser in situ keratomileusis excimer laser surgery. *J Cataract Refract Surg*. 2020;46(7):944-952.
6. Uthoff D, Pözl M, Hepper D, Holland D. A new method of cornea modulation with excimer laser for simultaneous correction of presbyopia and ametropia. *Graefes Arch Clin Exp Ophthalmol*. 2012;250(11):1649-1661.
7. Luger MH, Ewering T, Arba-Mosquera S. One-year experience in presbyopia correction with bi- aspheric multifocal central presbyopia laser in situ keratomileusis. *Cornea*. 2013;32(5):644-652.
8. Shetty R, Bar S, Sharma M, Dadachanji Z, Lalgudi VG. PresbyLASIK: A review of PresbyMAX, Supracor, and laser blended vision: principles, planning, and outcomes. *Indian J Ophthalmol*. 2020;68(12):2723-2731.
9. Luger MH, McAlinden C, Buckhurst PJ, Wolffsohn JS, Verma S, Arba Mosquera S. Presbyopic LASIK using hybrid bi-aspheric micro-monovision ablation profile for presbyopic corneal treatments. *Am J Ophthalmol*. 2015;160(3):493-505.
10. Baudu P, Penin F, Arba Mosquera S. Uncorrected binocular performance after bi- aspheric ablation profile for presbyopic corneal treatment using AMARIS with the PresbyMAX module. *Am J Ophthalmol*. 2013;155(4):636-647.
11. Epstein RL, Gurgos MA. Presbyopia treatment by monocular peripheral presbyLASIK. *J Refract Surg*. 2009;25(6):516-523.
12. Baudu P, Penin F, Arba Mosquera S. Uncorrected binocular performance after bi- aspheric ablation profile for presbyopic corneal treatment using AMARIS with the PresbyMAX module. *Am J Ophthalmol*. 2013;155(4):636-647, 647.e1.

13. Uthoff D, Pözl M, Hepper D, Holland D. A new method of cornea modulation with excimer laser for simultaneous correction of presbyopia and ametropia. *Graefes Arch Clin Exp Ophthalmol*. 2012;250(11):1649-1661.
14. Luger MH, Ewering T, Arba-Mosquera S. One-year experience in presbyopia correction with bi- aspheric multifocal central presbyopia laser in situ keratomileusis. *Cornea*. 2013;32(5):644-652.
15. Kohonen T, Böhm M, Herzog M, Hemkepler E, Petermann K, Lwowski K. Near visual acuity and patient-reported outcomes in presbyopic patients after bilateral multifocal aspheric laser in situ keratomileusis excimer laser surgery. *J Cataract Refract Surg*. 2020;46(7):944-952.
16. Luger MHA, McAlinden C, Buckhurst PJ, Wolffsohn JS, Verma S, Arba-Mosquera S. Long-term outcomes after LASIK using a hybrid bi-aspheric micro-monovision ablation profile for presbyopia correction. *J Refract Surg*. 2020;36(2):89-96.
17. Chan TC, Kwok PS, Jhanji V, Woo VC, Ng AL. Presbyopic correction using monocular bi-aspheric ablation profile (PresbyMAX) in hyperopic eyes: 1-year outcomes. *J Refract Surg*. 2017;33(1):37-43.
18. Arba-Mosquera S, Verma S, Awad ST. Theoretical effect of coma and spherical aberrations translation on refractive error and higher order aberrations. *Photonics*. 2020;7(4):116.
19. Fu D, Zhao J, Zhou XT. Objective optical quality and visual outcomes after the PresbyMAX monocular ablation profile. *Int J Ophthalmol*. 2020;13(7):1060-1065.
20. Zheleznyak L, Sabesan R, Oh JS, MacRae S, Yoon G. Modified monovision with spherical aberration to improve presbyopic through-focus visual performance. *Invest Ophthalmol Vis Sci*. 2013;54(5):3157-3165.
21. Holladay JT, Lynn MJ, Waring GO III, Gemmill M, Keehn GC, Fielding B. The relationship of visual acuity, refractive error, and pupil size after radial keratotomy. *Arch Ophthalmol*. 1991;109(1):70-76.
22. Miller D, Thibos L, Hong X. Requirements for segmented correctors for diffraction-limited performance in the human eye. *Opt Express*. 2005;13(1):275-89.

ALLON BARSAM, MD, MA, FRCOPHTH

- Founder, OCL Vision, London
- allon@oclvision.com
- Financial disclosure: Consultant (SCHWIND eye-tech-solutions)

DAVID KANG, MD

- Director, Eyereum Ophthalmic Clinic, Seoul, South Korea
- kangeye@eyereum.com
- Financial disclosure: Consultant (Carl Zeiss Meditec, SCHWIND eye-tech-solutions)



The SCHWIND ATOS femtosecond laser and the SCHWIND AMARIS excimer laser product family provide a comprehensive treatment portfolio for refractive and therapeutic corneal surgery. Find out about their many advantages at www.eye-tech-solutions.com